



## Letter to the Editor

## Epidemiological evidence concerning the association between onchocerciasis and epilepsy



In their editorial about our paper describing a high prevalence of epilepsy caused by ongoing *Onchocerca volvulus* transmission in the Aketi health zone (Democratic Republic of the Congo), Cantey and Sejvar remain skeptical about the association between onchocerciasis and epilepsy (Cantey and Sejvar, 2019; Mukendi et al., 2019). They cite the paper of Druet-Cabanac et al. as an example of a meta-analysis that did not find a significant association between onchocerciasis and epilepsy (Druet-Cabanac et al., 2004). However, two of the nine studies included in that review are problematic with regard to the investigation of the association between *O. volvulus* infection and epilepsy.

First, Kaboré et al. investigated a village that was already hypoendemic following more than 14 years of vector control activities by the Onchocerciasis Control Programme (OCP), possibly resulting in a low prevalence of onchocerciasis-associated epilepsy (OAE) (Kabore et al., 1996). Second, the study of Ovuga et al. described persons with epilepsy and/or retarded growth (Ovuga et al., 1992); when analyzing the findings of Ovuga et al., Druet-Cabanac et al. considered the participants with retarded growth as non-epileptic controls. Persons with retarded growth are not appropriate controls when investigating the association between epilepsy and onchocerciasis, as growth retardation itself might be onchocerciasis-related (Kipp et al., 1996). If these two studies were to be excluded from the meta-analysis (Figure 1), a common relative risk of 1.30 (95% confidence interval 1.04–1.62;  $p = 0.02$ ) would be obtained, instead of 1.21 (95% confidence interval 0.99–1.47;  $p = 0.06$ ) as reported.

When listing confounding factors related to epilepsy causality, the authors omit to mention that ivermectin use can influence the

outcome of case-control epilepsy studies (Mandro et al., 2018), hence masking the association between onchocerciasis and epilepsy. Most of the enumerated causal factors are ubiquitous in the tropics and result in a median epilepsy prevalence of only 1.4% in Sub-Saharan Africa (Ba-Diop et al., 2014). However, in Maridi (South Sudan), we recently documented an average epilepsy prevalence of 4.4% in onchocerciasis-endemic villages and 11.9% in the village closest to the Maridi dam (blackfly breeding site) (Colebunders et al., 2018a). The surveyed villages were void of pigs, thus excluding neurocysticercosis as a cause of epilepsy. Moreover, other causes of epilepsy were investigated and were not particularly frequent in the study area (Colebunders et al., 2018b), leaving onchocerciasis as the main explanation for these high numbers.

We agree that tools are already available to prevent and treat OAE. The challenge is that stakeholders are reluctant to recognize OAE as a public health problem; consequently, little is being done to address this issue despite the available evidence. While research should continue in order to elucidate the possible pathophysiological mechanisms behind OAE, interventions are urgently needed in the affected communities.

## Funding source

R. Colebunders receives funding from the European Research Council, grant No. 671055 (NSETIO).

## Ethical approval

Not applicable. No field research was performed, and all of the data reported in this letter were obtained from scientific publications.

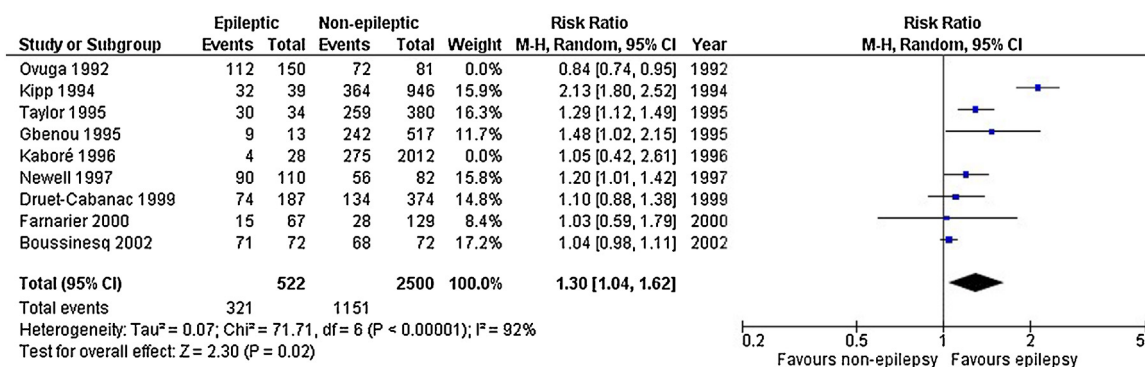


Figure 1. Meta-analysis and forest plot of studies investigating epilepsy and onchocerciasis.

## Conflicts of interest

The authors have no conflicts of interest to declare.

## References

- Ba-Diop A, Marin B, Druet-Cabanac M, Ngoungou EB, Newton CR, Preux P-M. Epidemiology, causes, and treatment of epilepsy in sub-Saharan Africa. *Lancet Neurol* 2014;13:1029–44.
- Cantey PT, Sejvar J. Onchocerciasis associated epilepsy—a question of causality. *Int J Infect Dis* 2019;79:185–6.
- Colebunders R, Carter JY, Olore PC, et al. High prevalence of onchocerciasis-associated epilepsy in villages in Maridi County, Republic of South Sudan: a community-based survey. *Seizure* 2018a;63:93–101.
- Colebunders R, Abd-Elfarag G, Carter JY, et al. Clinical characteristics of onchocerciasis-associated epilepsy in villages in Maridi County, Republic of South Sudan. *Seizure* 2018b;62:108–15.
- Druet-Cabanac M, Boussinesq M, Dongmo L, Farnarier G, Bouteille B, Preux PM. Review of epidemiological studies searching for a relationship between onchocerciasis and epilepsy. *Neuroepidemiology* 2004;23:144–9.
- Kabore JK, Cabore JW, Melaku Z, Druet-Cabanac M, Preux PM. Epilepsy in a focus of onchocerciasis in Burkina Faso. *Lancet Lond Engl* 1996;347:836.
- Kipp W, Bamuhiiiga J, Burnham G, Leichsenring M. The nakalanga syndrome in Kabarole District, Western Uganda. *Am J Trop Med Hyg* 1996;54:80–3.
- Mandro M, Suykerbuyk P, Tepage F, et al. Onchocerca volvulus as a risk factor for developing epilepsy in onchocerciasis endemic regions in the Democratic Republic of Congo: a case control study. *Infect Dis Poverty* 2018;7;. doi:http://dx.doi.org/10.1186/s40249-018-0465-9.
- Mukendi D, Tepage F, Akonda I, et al. High prevalence of epilepsy in an onchocerciasis endemic health zone in the Democratic Republic of the Congo, despite 14 years of community-directed treatment with ivermectin: a mixed-method assessment. *Int J Infect Dis* 2019;79:187–94.
- Ovuga E, Kipp W, Mungherera M, Kasoro S. Epilepsy and retarded growth in a hyperendemic focus of onchocerciasis in rural western Uganda. *East Afr Med J* 1992;69:554–6.

J.N. Siewe Fodjo

*Global Health Institute, University of Antwerp, Antwerp, Belgium*

F. Tepage

*Ministry of Health, Bas-Uélé, Congo*

R. Colebunders\*

*Global Health Institute, University of Antwerp, Antwerp, Belgium*

\* Corresponding author.

*E-mail address: robert.colebunders@uantwerpen.be (R. Colebunders).*

Corresponding Editor: Eskild Petersen, Aarhus, Denmark

Received 19 February 2019