

ONCHOCERCIASIS

Nodding syndrome: Preventable and treatable

Robert Colebunders^{1*} and Maarten J. Titulaer²

2017 © The Authors,
some rights reserved;
exclusive licensee
American Association
for the Advancement
of Science.

New insights into the pathophysiology of nodding syndrome, a form of childhood epilepsy associated with onchocerciasis, provide new opportunities for disease treatment and parasite control (Johnson *et al.*).

Until recently, nodding syndrome, a form of epilepsy in African children, was considered to be a mysterious, untreatable, and debilitating disease with high mortality (1–3). Recent evidence suggests that nodding syndrome may be triggered by infection with the parasitic worm *Onchocerca volvulus*, which causes the disease onchocerciasis (river blindness) (2). The exact pathophysiological mechanisms remain to be explained, but, as Johnson *et al.* (4) report in this issue, neurotoxic autoantibodies that cross-react with *O. volvulus* proteins could play a key role (Fig. 1). The authors analyzed sera and cerebrospinal fluid (CSF) from children with nodding syndrome and unaffected villagers as controls in onchocerciasis-endemic areas of Uganda and South Sudan. These investigators propose that cross-reactive autoantibodies enter the central nervous system in some patients infected with *O. volvulus* and cause the distinct neuronal pathology associated with nodding syndrome. They show that one of these autoantibodies is against leiomodin-1 (LM1), a protein expressed by neurons, and is found more frequently in persons with nodding syndrome compared to those without nodding syndrome from the same village.

The findings of Johnson and colleagues add to the growing evidence that nodding syndrome may be triggered by *O. volvulus* infection, but many questions remain regarding whether the cross-reactive autoantibodies they identify are pathogenic in this disease. For example, only 53% of nodding syndrome cases were LM1-positive compared to 31% of unaffected control villagers. Ideally, to link LM1 directly to *O. volvulus* infection, the study would have included individuals from other African regions not endemic for onchocerciasis as controls. The authors also report no correlation between LM1 autoantibodies and *O. volvulus* infection status, and LM1 autoantibodies were not restricted to patients with nodding syndrome. Stronger correlations may exist in this study but might have been obscured because serum and CSF samples were

obtained from patients several years after the onset of nodding syndrome. During this time lapse, the status of *O. volvulus* infection could have changed because of continuous exposure to *O. volvulus*-infected blackflies (the insect vector that transmits the parasite to humans) and use of the drug ivermectin to treat infected individuals (Fig. 1). Compared to unaffected control villagers, persons with nodding syndrome may be more likely to avoid rivers for risk of drowning and to take ivermectin because of skin lesions and itching associated with onchocerciasis. Ideally, to identify cross-reactive autoantibodies associated with nodding syndrome, serum and CSF samples would need to be analyzed before and immediately after symptoms emerge, which is difficult to do under field conditions.

The observed frequencies of autoantibodies in patients with nodding syndrome and controls depend on the cutoff values and tests chosen for discrimination. The authors performed cell-based assays, immunoblotting, and ELISA. ELISA has the advantage that it is a high-throughput assay and can provide semiquantitative results (within certain boundaries). A disadvantage is that ELISA is vulnerable to nonspecific background signals. The authors used serum samples from healthy individuals in the United States to determine cutoff values. These samples were drawn and handled under optimal conditions and were stored immediately. As the African samples were drawn and stored under suboptimal conditions, it is realistic to assume that these cutoff values may be too optimistic. The ideal control would have been uninfected individuals living in a nonendemic African region. An alternative would have been to correct for potential noise in the ELISA results by testing other autoantibodies not associated with nodding syndrome. Choosing a different test might have lowered the sensitivity but increased specificity.

The authors speculate that nodding syndrome may not be a single antibody syndrome but may be associated with multiple auto-

antibodies, one of which is against LM1. They also suggest that molecular mimicry with *O. volvulus* proteins may be involved. They show, *in silico*, regions of partial structural overlap between tropomyosin of the parasitic worm and LM1. They also demonstrate cross-reactivity of anti-LM1 autoantibodies with *O. volvulus* lysate and decreased immunoreactivity of these antibodies to LM1 after pre-absorption with this lysate. The results are tantalizing, but whether other autoantibodies are involved in molecular mimicry remains unclear.

The authors show that adding commercial antibodies or serum from a patient with nodding syndrome positive for LM1 autoantibodies to cultured neurons resulted in neuronal death; this was abrogated by using LM1 antibody-depleted serum. It would also be interesting to determine the specificity of the response to LM1 by establishing whether serum from LM1 antibody-negative nodding syndrome patients or LM1 antibody-positive unaffected control villagers would have a similar effect. Pathogenic antibodies generally mediate their effects by recognizing extracellular proteins expressed by neurons, so it will be interesting to elucidate how antibodies against LM1, an intracellular protein, may be exerting their neurotoxic effects (5). One could speculate that the real culprit is cytotoxic T cells, with autoantibodies being generated as a by-product of cytotoxic T cell action and neuronal cell death.

A high prevalence of nodding syndrome and other forms of epilepsy has been observed in onchocerciasis-endemic regions where the disease is poorly controlled by community-directed ivermectin treatment programs. Moreover, there is increasing evidence that nodding syndrome, other forms of epilepsy, and Nakalanga syndrome (a stunting disease often associated with epilepsy) are clinical presentations of onchocerciasis. Many of these cases occur in the same families and are clustered in villages with high onchocerciasis prevalence (2). This implies that they may be caused by the same trigger, most likely infection with *O. volvulus*. It will be interesting to investigate in future studies whether autoantibodies, including anti-LM1 autoantibodies, are present in persons with other forms of onchocerciasis-associated epilepsy.

¹Global Health Institute, University of Antwerp, Antwerp, Belgium. ²Department of Neurology, Erasmus University Medical Center, Rotterdam, Netherlands.

*Corresponding author. Email: robert.colebunders@uantwerpen.be

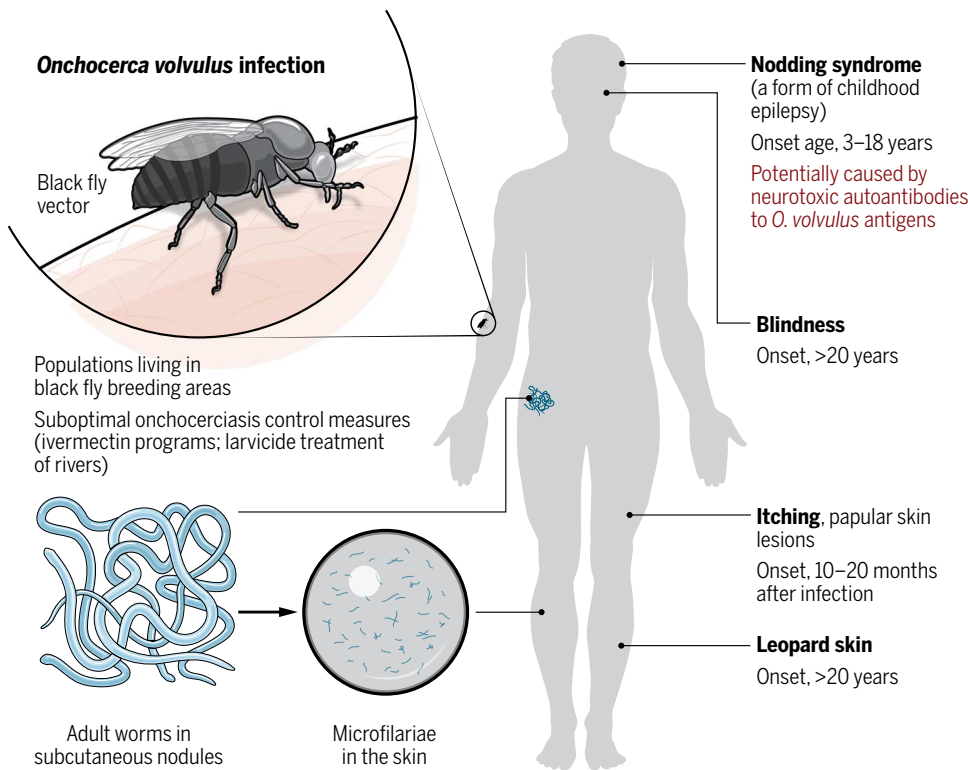


Fig. 1. Connecting the dots in onchocerciasis and nodding syndrome. In the absence of onchocerciasis control measures such as annual ivermectin treatment and larvicide treatment of rivers (breeding sites for the black fly vector), populations are at risk of becoming infected with the parasitic worm *O. volvulus* (3). Infection occurs when a black fly vector introduces *O. volvulus* larval microfilariae into the host during a blood meal. The microfilariae develop into adult worms, which reside in nodules in subcutaneous connective tissue. The adult female worms can produce thousands of microfilariae a day. The inflammatory reaction against dying microfilariae causes lesions in the skin and eyes and can result in blindness. *O. volvulus* infection is associated with a form of epilepsy in children called nodding syndrome. The exact pathophysiological mechanisms underlying nodding syndrome still need to be elucidated, but it is possible that autoantibodies against *O. volvulus* proteins that cross-react with a neuronal protein, LM1, result in the death of neurons in the central nervous system (4). The drug ivermectin is able to prevent clinical manifestations of onchocerciasis and may be able to prevent the onset of nodding syndrome.

Ultimately, we will need to perform a state-of-the-art postmortem study to unravel the pathophysiological mechanisms underlying nodding syndrome. Postmortems have been performed in Uganda, but because tissue was not processed in an optimal way, histological findings were not interpretable. A new post-mortem study is currently being planned in Uganda, which ideally would look at immunological infiltrates, immunophenotyping of cells, and complement activation in the brain tissue of nodding syndrome patients. In addition, IgG extraction and potentially metagenomic deep sequencing (6) might reveal important clues about pathophysiological mechanisms.

Nodding syndrome may not be curable, but it is treatable. Nodding syndrome treatment centers in Uganda have shown that with optimal antiepileptic treatment, ivermectin treatment, adequate nutrition, and psychosocial support, children may recover and be able to

return to school (7). Recovery is easier when nodding syndrome is diagnosed early and treatment is started without delay. Unfortunately, optimal antiepileptic treatment is often not available. Phenobarbital, the cheapest antiepileptic drug, does not seem to be effective for treating nodding syndrome. Sodium valproate is the drug of choice (8) but is not recommended in girls of childbearing age because of the risk of inducing congenital abnormalities. There is an urgent need to make other low-cost antiepileptic drugs available, and persons with nodding syndrome definitely should be treated with ivermectin. There is anecdotal evidence that ivermectin may decrease the frequency of seizures in persons with epilepsy in onchocerciasis-endemic regions. A clinical trial to investigate the effect of doxycycline on the frequency of seizures in persons with nodding syndrome is ongoing in Uganda, and a similar study to evaluate the ef-

fect of ivermectin is planned in the Democratic Republic of the Congo (2).

Aside from the pathophysiological mechanisms causing nodding syndrome, there are many other questions to be answered. The restricted geographical distribution of nodding syndrome relative to that of *O. volvulus* is still not well understood. The nodding syndrome epidemic in Uganda can most likely be explained by the displacement of hundreds of thousands of individuals who ended up in camps that were in close proximity to black fly-infested rivers during a period when ivermectin was not distributed (8). This could have caused an onchocerciasis epidemic followed by a nodding syndrome epidemic. In South Sudan, because of the war, people also had to leave their homes and hide in areas close to black fly-infested rivers (2).

Given the evidence that onchocerciasis may lead to epilepsy, the disease burden caused by onchocerciasis needs to be reassessed. Now, only skin lesions, itching, and blindness are considered to be complications of onchocerciasis (Fig. 1) (3). We now need to consider epilepsy. The effect of epilepsy on disability-adjusted life years is considerable, particularly in Africa, where there are limited resources to provide optimal treatment and care. It is important that the public health problem caused by onchocerciasis-associated epilepsy is clearly documented. During a rapid assessment in Mvolo, a village in the Western Equatoria state in South Sudan, one in six children was found to have some form of

epilepsy and 50% of the households had at least one child with epilepsy (2). In villages in several onchocerciasis-endemic regions in the Democratic Republic of the Congo, epilepsy prevalence rates are between 2 and 4% (2). This is about 10 times higher than in most non-onchocerciasis-endemic regions.

It is likely that onchocerciasis-associated epilepsy could have been prevented with better onchocerciasis control in many individuals. The nodding syndrome epidemic in northern Uganda started to decrease after 2008 when a limited number of people began ivermectin treatment. The epidemic then stopped in 2013 after the biannual distribution of ivermectin and implementation of larvicide treatment of two major rivers (9). In South Sudan, children continue to develop nodding syndrome because of lack of ivermectin treatment caused by insecurity in the region (2). It is known that ivermectin reduces skin microfilarial load very

rapidly (3), thus eliminating the potential trigger of epilepsy. It therefore seems plausible that high therapeutic coverage with ivermectin will decrease the incidence of onchocerciasis-associated epilepsy, but this will need to be confirmed in a prospective study. Improving onchocerciasis control, and ideally eliminating onchocerciasis altogether, is the way forward. The study by Johnson and colleagues clearly opens a new research direction that ultimately may lead to the unraveling of the pathophysiology of nodding syndrome and other forms of epilepsy associated with onchocerciasis. This may ultimately lead to the identification of additional therapeutic options for individuals with these types of epilepsy.

REFERENCES

1. G. Vogel, Mystery disease haunts region. *Science* **336**, 144–146 (2012).
2. R. Colebunders, A. Hendy, M. van Oijen, Nodding syndrome in onchocerciasis endemic areas. *Trends Parasitol.* **32**, 581–583 (2016).
3. U. Amazigo, M. Noma, J. Bump, B. Benton, B. Liese, L. Yaméogo, H. Zouré, A. Seketeli, Onchocerciasis, in *Disease and Mortality in Sub-Saharan Africa*, D. T. Jamison, R. G. Feachem, M. W. Makgoba, E. R. Bos, F. K. Baingana, K. J. Hofman, K. O. Rogo, Eds. (World Bank, Washington, DC, ed. 2, 2006).
4. T. P. Johnson, R. Tyagi, P. R. Lee, M.-H. Lee, K. R. Johnson, J. Kowalak, A. Elkahloun, M. Medynets, A. Hategan, J. Kubofcik, J. Sejvar, J. Ratto, S. Bunga, I. Makumbi, J. R. Aceng, T. B. Nutman, S. F. Dowell, A. Nath, Nodding syndrome may be an autoimmune reaction to the parasitic worm *Onchocerca volvulus*. *Sci. Transl. Med.* **9**, eaaf6953 (2017).
5. E. Lancaster, J. Dalmau, Neuronal autoantigens—Pathogenesis, associated disorders and antibody testing. *Nat. Rev. Neurol.* **8**, 380–390 (2012).
6. M. R. Wilson, N. M. Shanbhag, M. J. Reid, N. S. Singhal, J. M. Gelfand, H. A. Sample, B. Benkli, B. D. O'Donovan, I. K. M. Ali, M. K. Keating, T. H. Dunnebacke, M. D. Wood, A. Bollen, J. L. DeRisi, Diagnosing *Balamuthia mandrillaris* encephalitis with metagenomic deep sequencing. *Ann. Neurol.* **78**, 722–730 (2015).
7. A. S. Winkler, K. Friedrich, S. Velicheti, J. Dharsee, R. König, A. Nassri, M. Meindl, A. Kidunda, T. H. Müller, L. Jilek-Aall, W. Matuja, T. Gotwald, E. Schmutzhard, MRI findings in people with epilepsy and nodding syndrome in an area endemic for onchocerciasis: An observational study. *Afr. Health Sci.* **13**, 529–540 (2013).
8. J. F. Wamala, M. Malimbo, F. Tepage, L. Lukwago, C. L. Okot, R. O. Cannon, A. Laudisoit, R. Colebunders, Nodding syndrome may be only the ears of the hippo. *PLOS Negl. Trop. Dis.* **9**, e0003880 (2015).
9. R. Idro, H. Namusoke, C. Abbo, B. B. Mutamba, A. Kakooza-Mwesige, R. O. Opoka, A. K. Musubire, A. D. Mwaka, B. T. Opar, Patients with nodding syndrome in Uganda improve with symptomatic treatment: A cross-sectional study. *BMJ Open* **4**, e006476 (2014).

10.1126/scitranslmed.aam8532

Citation: R. Colebunders, M. J. Titulaer, Nodding syndrome: Preventable and treatable. *Sci. Transl. Med.* **9**, eaam8532 (2017).



Nodding syndrome: Preventable and treatable

Robert Colebunders and Maarten J. Titulaer (February 15, 2017)

Science Translational Medicine **9** (377), . [doi:

10.1126/scitranslmed.aam8532]

Editor's Summary

The following resources related to this article are available online at <http://stm.sciencemag.org>.
This information is current as of February 16, 2017.

Article Tools Visit the online version of this article to access the personalization and article tools:
<http://stm.sciencemag.org/content/9/377/eaam8532>

Related Content The editors suggest related resources on *Science's* sites:
<http://stm.sciencemag.org/content/scitransmed/9/377/eaaf6953.full>

Permissions Obtain information about reproducing this article:
<http://www.sciencemag.org/about/permissions.dtl>

Science Translational Medicine (print ISSN 1946-6234; online ISSN 1946-6242) is published weekly, except the last week in December, by the American Association for the Advancement of Science, 1200 New York Avenue, NW, Washington, DC 20005. Copyright 2017 by the American Association for the Advancement of Science; all rights reserved. The title *Science Translational Medicine* is a registered trademark of AAAS.